www.jpnim.com Open Access eISSN: 2281-0692
Journal of Pediatric and Neonatal Individualized Medicine 2020;9(1):e090138
doi: 10.7363/090138
Received: 2020 Mar 22; accepted: 2020 Mar 28; published online: 2020 Mar 28

Instant review

COVID-19 in newborns and in children: the state of the art

Valentina Paraluppi[1], Maria Cristina Pintus[2], Vassilios Fanos[3], Maria Antonietta Marcialis[2]

[1]School of Pediatrics, University of Cagliari, Cagliari, Italy

[2]Neonatal Intensive Care Unit, Azienda Ospedalera Universitaria, Cagliari, Italy

[3]Neonatal Intensive Care Unit, Azienda Ospedalera Universitaria and University of Cagliari, Cagliari, Italy

Abstract

Novel COronaVIrus Disease 2019 (COVID-19) is an emerging disease of public health concern because it is caused by a newly identified pathogen, against which humans have no pre-existing immunity. Since its outbreak, a growing number of studies have examined COVID-19 in adults, but the data on its epidemiological and clinical characteristics in newborns and in children are few and patchy. Children appear to develop moderate-mild or silent forms of the disease; to our knowledge, only two cases of death (a 14-year-old and a 16-year-old teenagers) have been reported. Arguably, the number of pediatric cases may be underestimated, since presumably cases with mild or no symptoms are not brought to the doctor's attention. We have selected the most interesting and significant papers (including some pre-publication or ahead-of-print papers). The key factors in the pathophysiology of COVID-19, available data on pregnancy, the neonatal period, and later are discussed. A review of pediatric cases is available and 3 practical algorithms help the reader in clinical choices. Finally, diagnostic criteria and treatment are presented.

Keywords

COVID-19, SARS-CoV-2, Coronavirus, pregnancy, newborn, infant, child, review.

Corresponding author

Vassilios Fanos, Neonatal Intensive Care Unit, Azienda Ospedaliero Universitaria and University of Cagliari, Cagliari, Italy; email: vafanos@jpnim.com.

How to cite

Paraluppi V, Pintus MC, Fanos V, Marcialis MA. COVID-19 in newborns and in children: the state of the art. J Pediatr Neonat Individual Med. 2020;9(1):e090138. doi: 10.7363/090138.

Introduction

Novel COronaVIrus Disease 2019 (COVID-19) is an emerging disease of public health concern because it is caused by a newly identified pathogen, against which humans have no pre-existing immunity.

Since its outbreak, a growing number of studies have examined COVID-19 in adults, but the data on its epidemiological and clinical characteristics in newborns and in children are few and patchy.

In adults, the severity of the disease can range from asymptomatic to causing severe interstitial pneumonia and death.

In children, it is not easy to determine the extent of the infection, because they seem to be less susceptible. Children appear to develop moderate-mild or silent forms of the disease and, to our knowledge, only one case of death, in a 14-year-old boy, has been reported in medical literature [1]. Arguably, the number of pediatric cases may be underestimated, since presumably cases with mild or no symptoms are not brought to the doctor's attention. Unfortunately, limited clinical identification, combined with children's intense community life and low adherence to hygiene standards, could lead to a significant increase in cases and the spread of the epidemic [2].

We have examined the relevant literature and we have selected the most interesting and significant papers. Note that some are pre-publication or ahead-of-print papers.

2019 novel Coronavirus (SARS-CoV-2)

Coronaviruses are a large family of viruses that cause illness ranging from common colds to more serious diseases, such as Middle Eastern Respiratory Syndrome (MERS) and Severe Acute Respiratory Syndrome (SARS). Coronaviruses have large single-stranded RNA genomes, with a crown-like appearance under an electron microscope. The Orthocoronavirine subfamily of the Coronaviridae is classified into four Coronavirus (CoV) genera: Alpha-, Beta-, Delta- and Gammacoronavirus. The Betacoronavirus genus is further separated into five subgenera (including Sarbecovirus).

The novel Coronavirus, which is responsible for the respiratory disease now called COVID-19, is closely related to SARS-CoV and is genetically classified within the subgenus Betacoronavirus Sarbecovirus [3]. Thus, the virus causing the current Coronavirus outbreak has been called 'Severe acute respiratory syndrome Coronavirus 2' (SARS-CoV-2) and the disease it causes has been named 'COVID-19' (where 'CO' stands for 'corona', 'VI' for 'virus', 'D' for 'disease' and '19' indicates the year in which it occurred). **In order to simplify this discussion, we will conventionally use the term COVID-19 also to refer to the SARS-CoV-2.**

The key factors in the pathophysiology of COVID-19

Similarly to what has been shown for SARS, recent studies and analyses indicate that Angiotensin-Converting Enzyme 2 (ACE2) could be the host receptor for COVID-19 [4]. ACE2 is located on the surface of type II pneumocytes and also in the gut, heart, oral cavity, kidney, testis and placenta [5-9].

ACE2 regulates the renin-angiotensin system (RAS) by counterbalancing the Angiotensin-Converting Enzyme (ACE) activity. ACE cleaves angiotensin I to generate angiotensin II, whereas ACE2 inactivates angiotensin II to form angiotensin 1-7 negatively regulating the system. In mice, ACE2 and the angiotensin II type 2 receptor (AT2) protect the animal from severe acute lung injury induced by acid aspiration or sepsis. Other components of the RAS, including ACE, angiotensin II and the angiotensin II type 1a receptor (AT1a), promote disease pathogenesis, induce lung edema, vasoconstriction and a proinflammatory state, and induce tissue fibrosis in the heart and lung [10, 11]. The viral spike protein (S protein) is cleaved by cathepsin, furin protease and transmembrane protease serine 2 (TMPRSS2) into subunits S1 and S2. S1 contains the receptor-binding domain which allows Coronaviruses to directly bind to the peptidase domain of ACE2. Subsequently, S2 plays an important role in the infection because it facilitates the fusion between the virus and the host cell membrane [4]. Once inside, the virus releases its RNA into the cytoplasm. The viral entry and replication together with the action of angiotensin II via the AT1 receptors cause severe lung injury (**Fig. 1**).

In light of the above mechanisms, the following potential therapeutic approaches have been proposed:

- a COVID-19 S protein-based vaccine;
- a TMPRSS2 inhibitor to block the priming of the spike protein [4];
- antibodies or small molecules that could block ACE2 receptor at the interaction sites between ACE2 and COVID-19;
- use of angiotensin II receptor blockers (like telmisartan or losartan) available for clinical use as potential drugs to control viral spread [12].

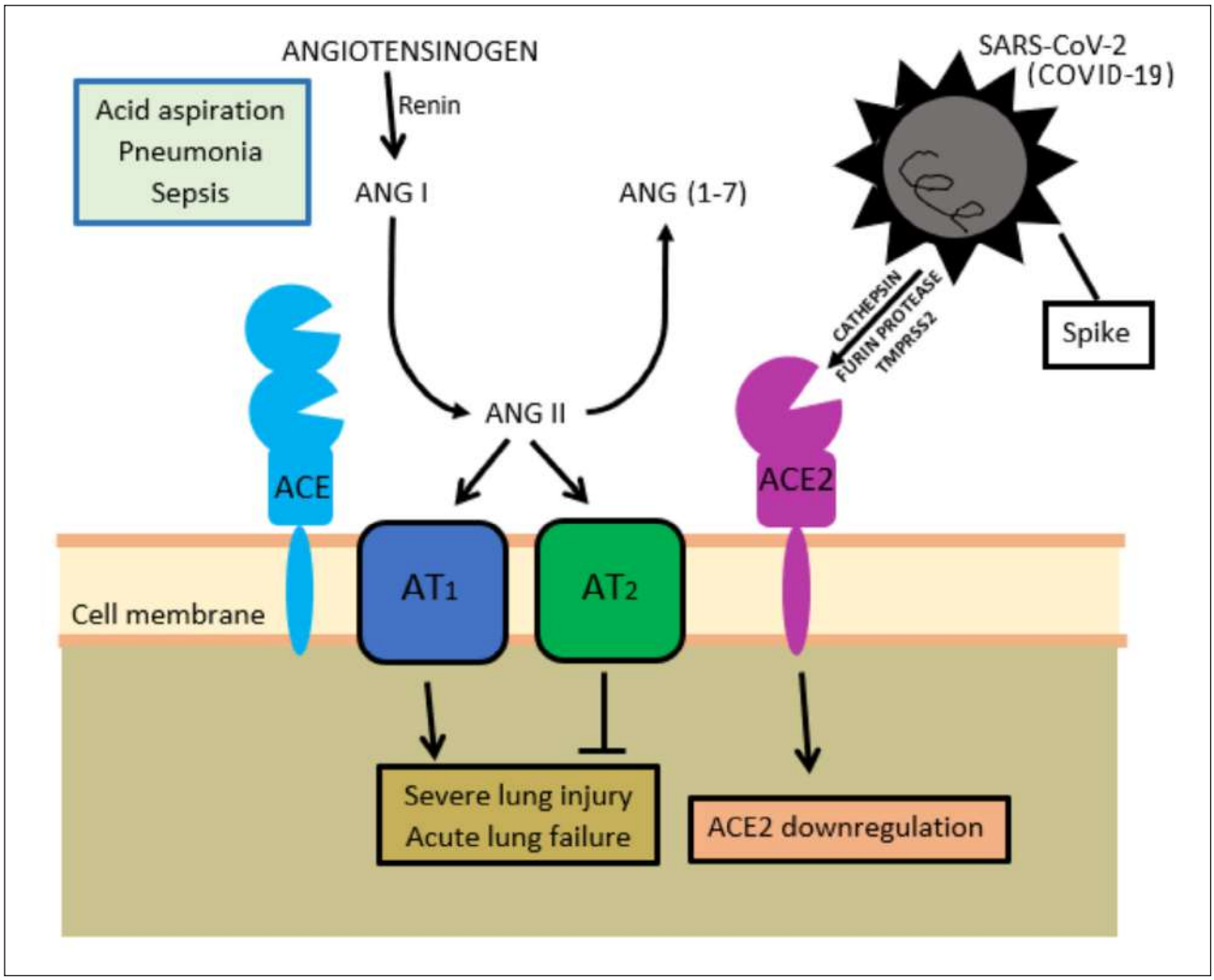

Figure 1. The role of RAS (renin-angiotensin system) in acute lung failure. Modified from: Hoffmann et al., 2020 [4], and Kuba et al., 2006 [11] .

This figure sets out the role of RAS in acute lung failure and proposes COVID-19 interaction with ACE2 (Angiotensin-Converting Enzyme 2). ACE (Angiotensin-Converting Enzyme) cleaves ANG I (angiotensin I) to generate ANG II (angiotensin II), which in turn induces acute lung failure through stimulation of the angiotensin II type 1 receptor (AT1), whereas ACE2 inactivates ANG II to form ANG 1-7 (angiotensin 1-7) negatively regulating the system. In mice, ACE2 and the angiotensin II type 2 receptor (AT2) protect from severe acute lung injury induced by acid aspiration or sepsis [11]. On the other hand, the viral spike protein (S protein) is cleaved by cathepsin, furin protease and TMPRSS2 (transmembrane protease serine 2) into subunits, S1 and S2. S1 contains the receptor-binding domain which allows Coronaviruses to directly bind to the peptidase domain of ACE2. Subsequently, S2 plays an important role in the infection because it promotes the fusion between the virus and the host cell membrane. Once inside, the virus releases its RNA into the cytoplasm [4].

The expression of ACE2 may change according to age, gender, race and underlying conditions such as diabetes, hypertension, coronary heart disease and cerebrovascular disease [13, 14]. Furthermore, some drugs like ACE inhibitors, AT2 blockers and ibuprofen could increase ACE2 expression, which might facilitate the infection with COVID-19 [15]. These data are very contrasting. It seems clear that several factors, in addition to ACE2 receptors, are involved in lung damage during viral infection, first of all, inflammatory mediators [16].

In order to counter immune overreaction that can damage lung tissue, antirheumatic drugs such as hydroxychloroquine or tocilizumab are being used.

COVID-19 and pregnancy

According to the first published case series of 19 pregnant women with clinical symptoms of COVID-19, the virus was not detected in amniotic fluid or in the neonatal blood taken from the umbilical cord [17].

Moreover, 9 mothers who were infected during the third trimester of pregnancy delivered by Cesarean section 9 healthy uninfected infants [17].

It should be stressed that pathology examination of the placenta of 3 pregnant women with COVID-19 infection who gave birth by Cesarean section showed no morphological changes related to

the viral infection, and that the search for the virus in the placental tissue was negative. The swabs of the 3 newborns were also negative [18].

Due to the very low expression of ACE2 receptors in almost all cell types of the early maternal-fetal interface, COVID-19 cannot be passed from mother to fetus via transplacental vertical transmission [9].

However, during vaginal delivery, active pushing while wearing a mask would be difficult for the mother; therefore, the newborn may catch the infection at birth from droplets or stool. Lastly, if a newborn stays in close contact with the infected mother, it is likely to become infected [19].

Therefore, the limited case series currently available show no evidence of vertical transmission of COVID-19. However, the news media have reported one case of possible vertical transmission of the infection in the womb, identified on 13 March 2020. The pharyngeal swab on the newborn, taken just a few minutes after birth was positive, but contamination cannot be excluded.

In China, the expert consensus is that for COVID-19-positive mothers Cesarean delivery is preferable [2, 20]; however, the '*Guidelines for pregnant women with suspected SARS-CoV-2 infection*' encourage spontaneous vaginal delivery, where possible [21].

All studies agree that water birth is not indicated for COVID-19-positive women, due to evidence of fecal transmission of the virus.

COVID-19 in newborns

Thus far, only a few newborns born to COVID-19-infected mothers have tested positive [22].

The first report concerned a full-term newborn (40 weeks, 3,205 g) whose mother was symptomatic and lived near the Huanan Seafood Wholesale Market in Wuhan. Although the mother had not been to the market during pregnancy, other people living in the same community had. Therefore, that market is thought to be the source of the infection. An emergency Cesarean section was performed, during which the mother was wearing an N95 mask. Immediately after birth, the baby was healthy (Apgar scores 8 and 9 at 1 and 5 minutes, respectively) and had no contact with the mother. After 30 minutes, he vomited, after which he was isolated and closely monitored. His blood tests showed lymphopenia, abnormal liver function tests and elevated creatine kinase levels. The infant's pharyngeal swab specimen, collected 36 hours after birth, was positive. The mother's breast milk was negative for COVID-19. Despite the normal vital signs, the newborn's chest CT revealed a high-density nodular shadow under the pleura of the posterior segment of the upper lobe of the right lung. Eventually, the newborn was discharged healthy at 16 days of age [22].

Another case concerned a 17-day-old baby who tested positive for COVID-19 and suffered from fever, cough and vomit. In his family, the first case of infection was detected in the maid, followed by the mother. A third newborn, born to an infected mother, developed a fever at 5 days of age. A fourth case was a newborn to an infected but undiagnosed mother, and was diagnosed 30 days after birth. Shortness of breath, vomiting, coughing and fever were present in all newborns. These infants' vital signs were stable and their symptoms were mild. To date no severe cases of COVID-19 have been reported in newborns [23-26].

The Chinese Working Committee on Perinatal and Neonatal Management for the Prevention and Control of the 2019 Novel Coronavirus Infection has recently published a consensus based on a systematic review of recent studies on COVID-19 but also of earlier studies on SARS-CoV and MERS-CoV [20].

Comment of the authors: although there are many similarities between COVID-19 and SARS-CoV, notably a high correspondence (86%) of the whole genome, the involvement of the same receptor (ACE2) and the same routes of transmission (respiratory droplets and stool), there are also differences.

Firstly, COVID-19 shows mild symptoms but higher transmissibility and speed of spread than SARS [27].

Secondly, several studies have confirmed the lack of vertical transmission and the absence of clinical manifestations associated with the mother's infection, except for a higher frequency of prematurity [28-30].

According to the experts, the infected newborn may be asymptomatic or show mild or severe symptoms. The incubation period is generally 3-7 days but the shortest was 1 day [31]. Detection of a highly homologous sequence with known COVID-19 in the upper respiratory tract, lower respiratory tract, sputum, endotracheal aspirate, bronchoalveolar lavage or serum are required for the diagnosis.

Neonatal clinical manifestations associated with COVID-19 especially in premature infants are often not specific: temperature instability, tachypnea,

grunting, nasal flaring, increased work of breathing (apnea), cough, tachycardia, feeding difficulties, lethargy, vomiting, diarrhea and abdominal distension [20].

An early laboratory exam may show normal or decreased leukocyte counts, or decreased lymphocyte counts. Mild thrombocytopenia and elevated levels of creatine kinase, alkaline phosphatase, alanine aminotransferase, aspartate aminotransferase and lactate dehydrogenase may be detected [20].

The lung ultrasound or chest radiography are likely to show pneumonia. Abdominal radiography may show intestinal ileus [20].

The Chinese Committee defined newborns suspected of COVID-19 infection as those born to mothers with a history of COVID-19 infection between 14 days before delivery and 28 days after delivery, or newborns directly exposed to people infected with COVID-19.

Fig. 2 shows a flow chart for assessing and investigating suspected cases in newborns,

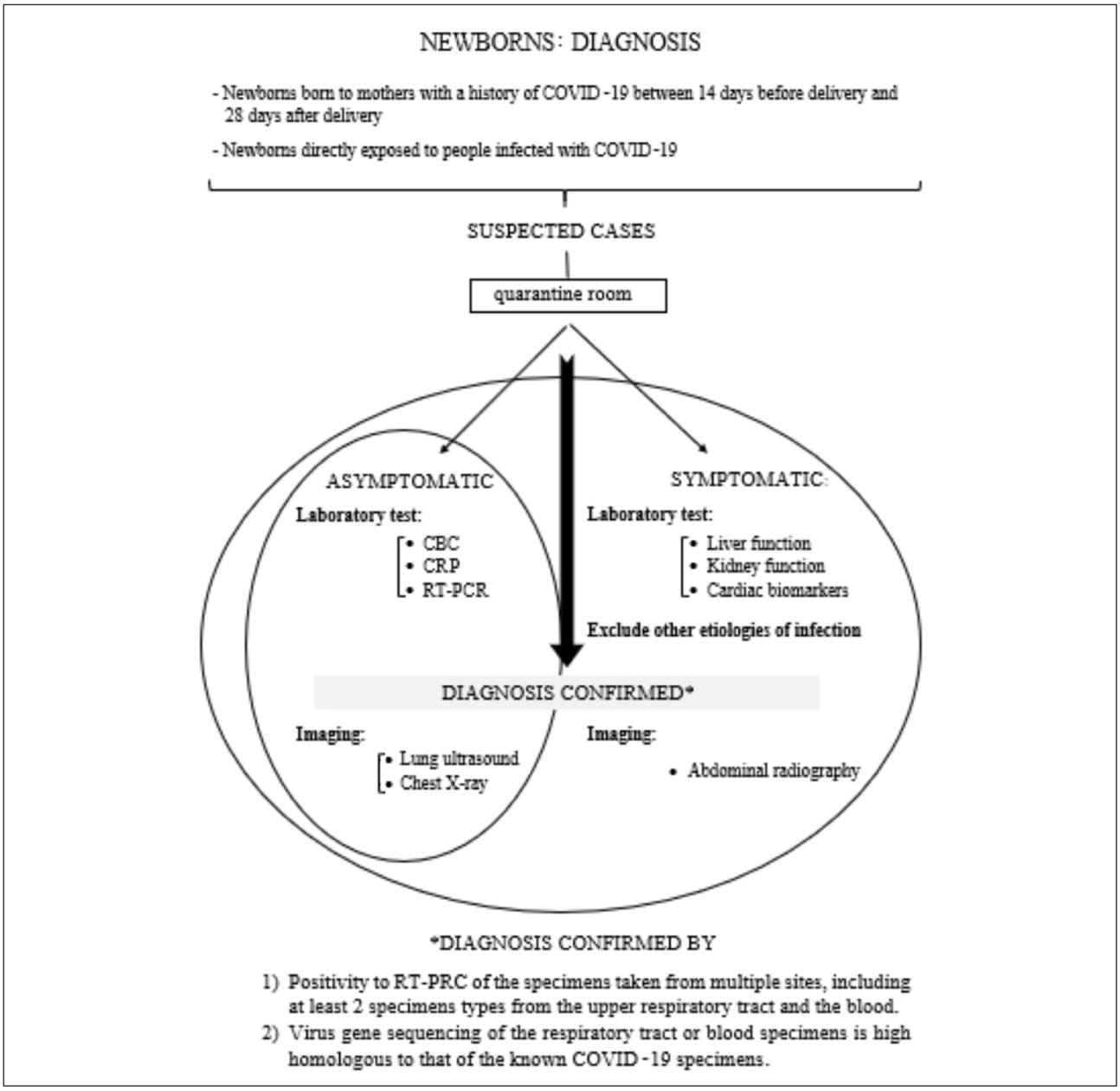

Figure 2. The management process for suspected and confirmed COVID-19 cases in newborns. Modified from: Wang et al., 2020 [20].

Once suspected newborns are admitted to quarantine rooms, asymptomatic cases undergo the following laboratory tests: CBC (complete blood count), CRP (C-reactive protein) and RT-PCR (real-time fluorescence polymerase chain reaction). Symptomatic suspected cases are additionally tested for liver function, kidney function and cardiac biomarkers and to exclude other etiologies of infection. Once diagnosis has been confirmed, lung ultrasound or chest X-ray are recommended in asymptomatic cases, plus abdominal radiography in symptomatic cases [20].

regardless of whether they present symptoms or not.

All suspected cases should be admitted to the quarantine ward.

The expert consensus recommends that mothers with suspected COVID-19 infection be placed in a negative-pressure delivery room.

Physicians must wear protective equipment, including hats, goggles, N95 masks, protective suits and gloves.

Delayed cord clamping, mother-baby contact and breastfeeding are not recommended.

Suspected newborns should be placed in an incubator in a separate room from **infected newborns**; both must be isolated and cared for nurses and doctors wearing protective equipment.

Strict protocols for entering and exiting the quarantine ward must be put in place and followed.

For infants with severe acute respiratory distress syndrome, high-dose surfactant, inhaled nitric oxide, and high-frequency oscillatory ventilation (HFOV) may be effective.

In more severe cases, continuous renal replacement therapy and extracorporeal membrane oxygenation (ECMO) may be necessary.

For critical patients, a multi-disciplinary team involving neonatal and intensive care specialists, pulmonologists, radiologists, specialists of infection and specialist nurses may be required.

Discharge criteria for COVID-19 patients vary depending on clinical features and are summarized in **Fig. 3** [20].

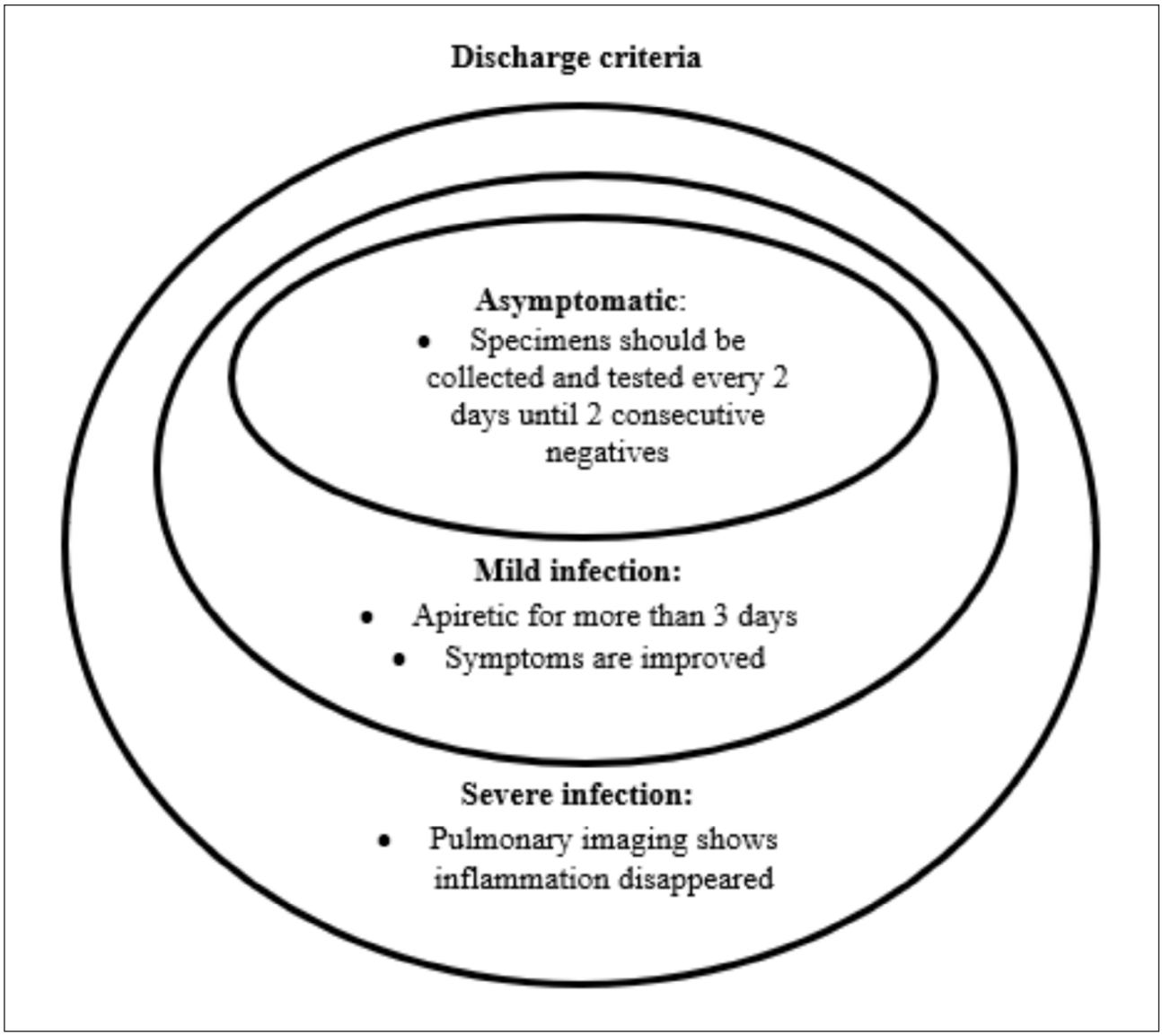

Figure 3. Discharge criteria in newborns with confirmed COVID-19. Modified from: Wang et al., 2020 [20].
Patients are divided into 3 groups: asymptomatic, mild infection and severe infection. An essential condition for discharge is to have 2 negative tests for COVID-19 at 24-hour intervals [20].

COVID-19 after the neonatal period

By 30 January 2020, of the 9,692 confirmed cases reported in China, a total of 28 were children (aged from 1 month to 17 years) [32]. In February, WHO-China stated that 2.4% of all reported cases were aged ≤ 18 years. We do not as yet have complete clinical and epidemiological data on the pediatric population.

A recent pre-publication retrospective epidemiological study examined the characteristics and the transmission patterns of 2,143 pediatric patients with COVID-19 (731 confirmed and 1,412 suspected). Out of the total cases, 1,213 (56.6%) were boys. Over 90% of all patients were asymptomatic, mild or moderate cases. Severe or critical cases were much fewer than in adult patients (5.9% vs 18.5%) [33].

Even though children present mild forms of COVID-19, that does not mean that we should ignore those who have the disease. We have to take all measures of prevention: in fact children harbour large amounts of virus, even if asymptomatic, and viruses can persist in feces for a long time, even if they are absent from nasopharingeal secretions [34].

Another study [35] including 10 children with COVID-19 reported milder respiratory infections compared to the adult cases. Fever and mild cough are the most common symptoms at the onset of the disease. In mild cases, the fever is short and resolves quickly.

The first pediatric case of COVID-19 detected in Singapore was a 6-month-old boy. The infant was admitted to the hospital because his mother and live-in helper were undergoing investigations for COVID-19. Initially, the child was asymptomatic but the viral load detected by the nasopharyngeal swab was very high. On day 2 of admission, during the viremic phase he had a single transient temperature of 38.5°C. On day 9 of admission, COVID-19 RNA was also detected in the stool of the infant. In this patient, nasopharyngeal swabs became negative on day 17 of admission [36].

Tab. 1 summarizes the data from two recent studies on pediatric cases of COVID-19.

The first study was a research letter published in *JAMA* on 14 February 2020. The researchers identified all infected infants (9 infants, age range 1-11 months) hospitalized between 8 December 2019 and 6 February 2020 in China. Seven patients were female. Four patients had fever, 2 had mild upper respiratory airway symptoms and 1 had no symptoms but tested positive for COVID-19. None of them required intensive care or mechanical ventilation, or had any severe complications [37].

The second study included 6 hospitalized infected children (range 1-7 years) admitted from 7 to 15 January. Four patients were female. All the patients suffered from fever and were treated with antivirals, antibiotic agents and supportive therapies. Only a 3-year-old girl was seriously ill and was admitted to the Pediatric Intensive Care Unit. She was treated with immune globulin from healthy donors and discharged after 13 days of hospitalization [38].

Xu et al. [39] reported epidemiological and clinical investigations on 10 pediatric cases of COVID-19 (age 2 months to 15 years), of whom 6 were male and 4 female. They were identified because of their exposure history, and the diagnosis was confirmed by real-time PCR with reverse transcription. The most common symptoms were cough, sore throat, nasal congestion, rhinorrhea and diarrhea. Differently from adult people, none had lethargy or dyspnea. One child was asymptomatic. Chest X-rays were normal or revealed only coarse lung markings. CT scans were abnormal in half of the cases, with isolated or multiple patchy ground-glass opacities. In contrast with adult patients, the majority of blood tests were normal and only a few cases showed leukopenia, lymphopenia or elevated transaminase. Seven had elevated interleukin (IL)-17F, 5 had an increase of IL-22 and 5 had an elevation of IL-6. Notably, 8/10 patients had RT-PCR-positive rectal swabs even after nasopharyngeal testing were negative, revealing persistent fecal viral shedding.

Xia et al. [40] underline the unique clinical and CT features in pediatric patients: in the early stage of the infection, the test for COVID-19 RNA in children could give a false negative result. Moreover, coinfection is common in these patients. Consolidation with surrounding halo sign was observed in half of the patients and was considered as a typical imaging sign in pediatric COVID-19.

Diagnostic criteria

The diagnostic criteria for COVID-19 in children, which include epidemiological history and clinical and radiological characteristics, are summarized in **Fig. 4** [31].

Table 1. Characteristics of the 15 pediatric cases. Modified from: Wei et al., 2020 [37] and Liu et al., 2020 [38].

Characteristic	Patient No.														
	1	2	3	4	5	6	7	8	9	10	11	12	13	14	15
Age	1 mo 26 d	3 mo	3 mo 22 d	6 mo	7 mo	8 mo	9 mo	10 mo	11 mo	1 y	3 y	3 y	3 y	4 y	7 y
Sex	F	F	F	M	F	F	F	M	F	M	F	F	F	M	F
Symptoms	Runny nose, cough	Cough, sputum production	Fever	NR	Fever	None	Fever	NR	Mild fever	Patchy shadows in both lungs, fever	Patchy ground opacities in both lungs, fever	Patchy shadows in both lungs, fever	Patchy shadows in both lungs, fever	Fever	Fever
Linked to Wuhan	YES	YES	NR	NO	YES	YES	YES	YES	YES	YES	YES	YES	NR	YES	YES
Clinical course															
Duration of fever (days)	NR	NR	NR	NR	NR	NR	NR	NR	NR	6	11	4	7	6	3
Hospitalization (days)	YES	YES	YES	YES	YES	YES	YES	YES	YES	YES (5)	YES (13)	YES (10)	YES (7)	YES (8)	YES (7)
ICU admission	NO	NO	NO	NO	NO	NO	NO	NO	NO	NO	**YES**	NO	NO	NO	NO
Treatments															
Ribavirin	NR	NR	NR	NR	NR	NR	NR	NR	NR	NO	YES	NO	NO	YES	NO
Oseltamivir	NR	NR	NR	NR	NR	NR	NR	NR	NR	YES	YES	YES	YES	YES	YES
Glucocorticoids	NR	NR	NR	NR	NR	NR	NR	NR	NR	YES	YES	YES	YES	NO	NO
Supplemental oxygen	NR	NR	NR	NR	NR	NR	NR	NR	NR	NO	YES	NO	NO	NO	NO
Intravenous immune globulin	NR	NR	NR	NR	NR	NR	NR	NR	NR	NO	YES	NO	NO	NO	NO
Severe complications	NO	NO	NO	NO	NO	NO	NO	NO	NO	NR	NR	NR	NR	NR	NR

Only a 3-year-old girl was admitted to the Intensive Care Unit (ICU).
Some data are not reported (NR) because they were not provided in the original tables [37, 38].

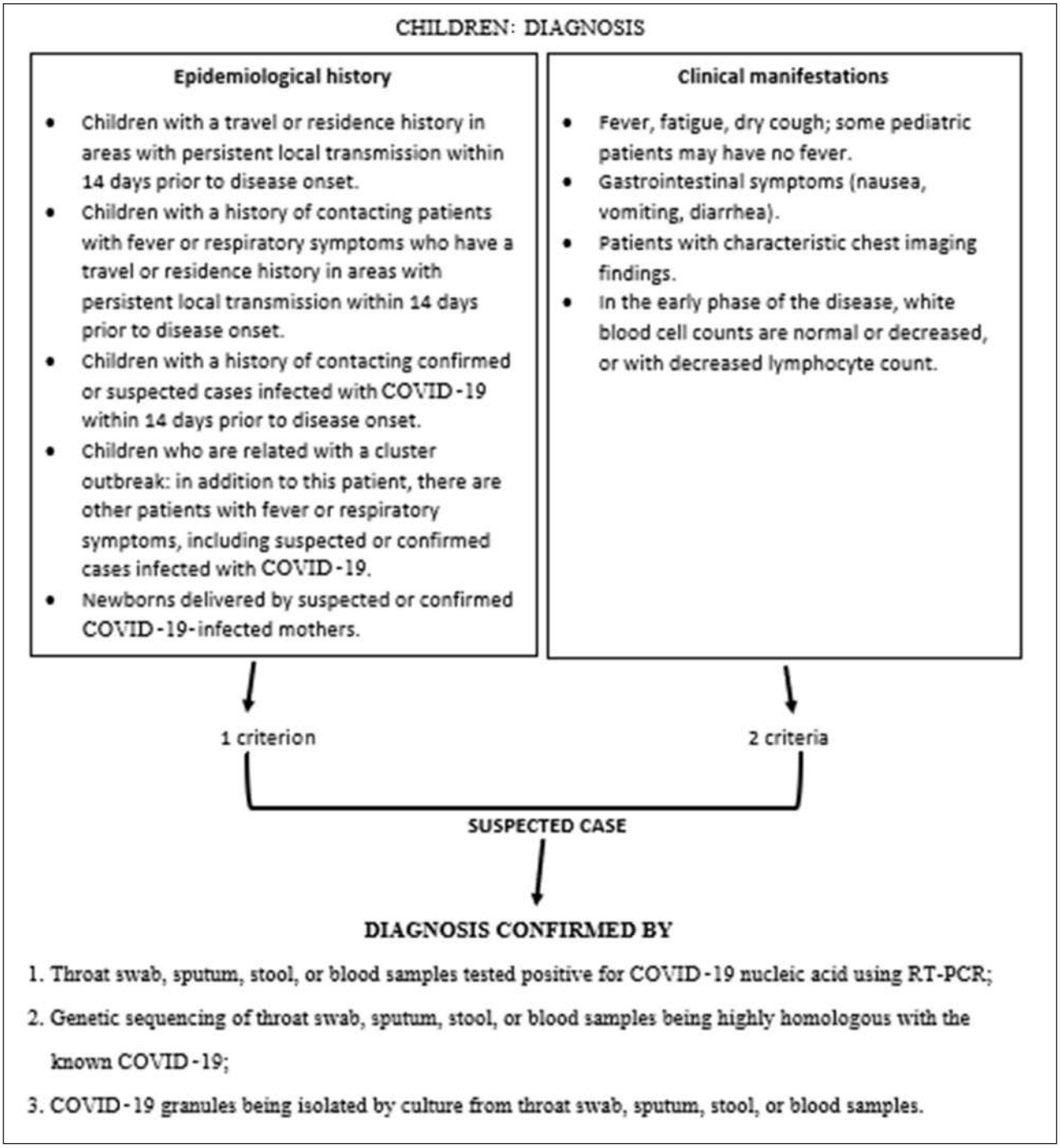

Figure 4. Diagnostic criteria in children with suspected COVID-19. Modified from: Chen et al., 2020 [31].
One epidemiological criterion plus two clinical manifestations are the basis for selecting suspected cases who need to be tested for COVID-19 in swabs collected from multiple sites and in blood [31].

Diagnosis is based on two positive naso-pharyngeal swabs (RT-PCR nucleic acid search) or, alternatively, one positive bronchoalveolar lavage. The second procedure is not recommended in clinical practice, to avoid the risk of superinfections [31, 41].

The key messages to be stressed are early identification of the disease, promptly followed by effective isolation measures and appropriate treatment. Even if the common respiratory pathogen tests are positive, children who have a history of close contact with COVID-19 should also receive prompt COVID-19 pathogen testing [31].

General treatment

General treatment consists in bed rest, ensuring calories, water and electrolytes intake. In febrile

children, (> 38.5°C) oral acetaminophen (10-15 mg/kg every 4-6 hours) should be given [31, 32].

Respiratory support

If hypoxia occurs, oxygen therapy is mandatory and, where necessary, nasal high-flow therapy or non-invasive ventilation should be used. If children who undergo non-invasive ventilation do not improve, invasive ventilation using lung-protective strategies is recommended. If necessary, prone position ventilation, lung recruitment and, in severe cases, ECMO can be applied [31, 32].

Pharmacological therapy

At present, no specific medication has been proven to be effective against COVID-19; however, the current protocols **for adults** [42] include:

- empirical antibiotic therapy (e.g. ceftriaxone + clarithromycin; at usual dosage);
- antiviral therapy lopinavir/ritonavir 400/100 mg capsule, 2 x 2/day; alternatively, in more severe cases remdesivir 200 mg IV as loaded dose, then 100 mg/day IV (days 2-10);
- anti-rheumatic drugs such as hydroxy-chloroquine 200 mg capsule, 1 x 2/day for at least 5-7 days or tocilizumab;
- interferon alpha can reduce viral load (nebulization 200,000-400,000 IU/kg in 2 mL sterile water, 2/day for 5-7 days, 1-2 sprays on each side of the nasal cavity, 8-10 sprays on the oropharynx);
- no steroids; WHO advises against their use, on the basis of data from MERS and SARS, where they seemed to worsen prognosis.

The efficacy of these treatments has still to be determined.

Moreover, newborns and children generally have a mild clinical presentation.

This is why treatment is essentially symptomatic and supportive (IV rehydration, oxygen therapy).

Infants with severe respiratory distress can be treated with surfactant, nitric oxide inhalation, HFOV and ECMO if necessary [31, 32].

Newborns and children do not usually require drug therapy; in those cases that required antiviral therapy no dosage was reported.

Finally, evidence shows that plasma from convalescent patients can be used as treatment [43].

Conclusions

Currently, there is no evidence indicating vertical transmission of COVID-19. However, due to the limited number of cases and because the epidemiological and clinical pattern of COVID-19 is still unclear, newborns of mothers with confirmed or suspected COVID-19 are still considered at high risk. They should be isolated and monitored regardless of whether they have symptoms or not.

The age of disease onset in children ranges from 1 day to 17 years. Infants and children may be asymptomatic or show fever and low-mild grade respiratory symptoms. Less frequently, they suffer from abdominal pain, nausea, vomiting and diarrhea [31, 32].

Infants and children might be largely spared by COVID-19 thanks to the immaturity of their immune system.

In early-stage COVID-19, RNA detection in pharyngeal swab specimens may be negative. In addition, even after nasopharyngeal tests are negative, real-time RT-PCR rectal swabs may continue to be positive. In the early phase of the disease, white blood cell count is normal or decreased or with decreased lymphocyte count. Liver enzymes, muscle enzymes and myohemoglobin levels can be increased in some patients. Most patients display elevated C-reactive protein levels and normal procalcitonin levels. In the severe cases, D-dimer is high [31, 32].

Differential diagnosis of coinfection by COVID-19 and other viruses and/or bacteria should be considered [31, 32].

Suspected patients should be isolated in a single room or, depending on their medical conditions, can be left at home [32].

Last-second data

The purpose of this instant review is to highlight some neonatal pediatric aspects of COVID-19. To our knowledge, we have provided an overview of the present cases in pediatrics as at 19 March 2020. However, this topic needs to be continuously updated.

A recent review [44], published on 18 March, evaluated 171 children with COVID-19 treated at the Wuhan Children's Hospital. In order to highlight the clinical features of COVID-19 in children we have summarized the signs and symptoms in **Fig. 5** [44].

In a recent research letter published in the *New England Journal of Medicine* on 26 March [45], it

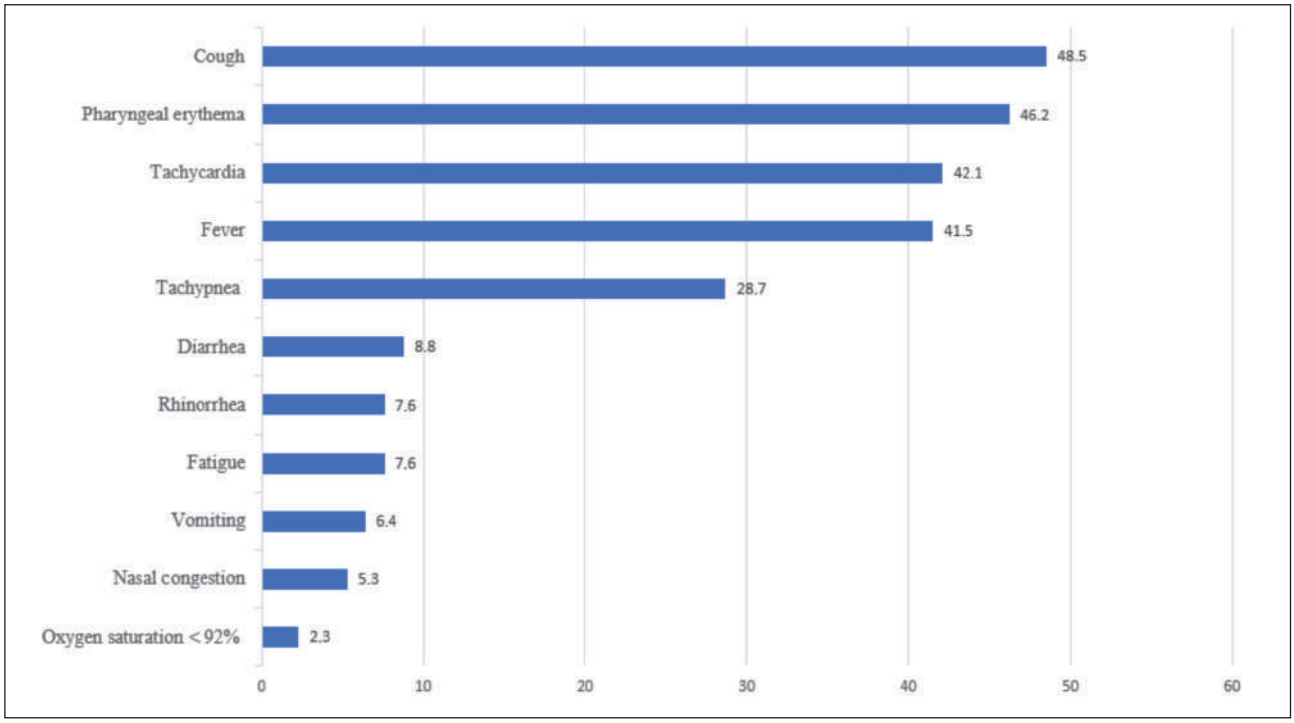

Figure 5. Frequencies of the most common sign and symptoms in a child population with COVID-19. Modified from: Lu et al., 2020 [44].

is hypothesized a possible vertical transmission of COVID-19 from an infected mother to her newborn. A *JAMA* Editorial on this letter suggested that a more definitive evidence is needed on this topic [46].

An updated document of the Italian Society of Neonatology, published on 22 March [47], underlines that the indication to avoid breastfeeding, suggested by some authors [21], does not fully consider the well-documented benefits of maternal milk [48].

Finally, last-second news report the death of a young girl (16 years old) in France, confirming again the dangerousness of COVID-19 [49].

Declaration of interest

The Authors declare that there is no conflict of interest.

References

1. Dong Y, Mo X, Hu Y, Qi X, Jiang F, Jiang Z, Tong S. Epidemiological Characteristics of 2143 Pediatric Patients With 2019 Coronavirus Disease in China. Pediatrics. 2020 Mar 16. [Epub ahead of print].
2. Giacomet V, Stracuzzi M, Rubinacci V, Zuccotti GV. SARS-CoV-2: Quali implicazioni nella popolazione pediatrica. Medico e Bambino. 2020;39(2):93-6.
3. Lu R, Zhao X, Li J, Niu P, Yang B, Wu H, Wang W, Song H, Huang B, Zhu N, Bi Y, Ma X, Zhan F, Wang L, Hu T, Zhou H, Hu Z, Zhou W, Zhao L, Chen J, Meng Y, Wang J, Lin Y, Yuan J, Xie Z, Ma J, Liu WJ, Wang D, Xu W, Holmes EC, Gao GF, Wu G, Chen W, Shi W, Tan W. Genomic characterization and epidemiology of 2019 novel coronavirus: implications for virus origins and receptor binding. Lancet. 2020;395(10224):565-74.
4. Hoffmann M, Kleine-Weber H, Krüger N, Müller M, Drosten C, Pöhlmann S. The novel coronavirus 2019 (COVID-19) uses the SARS-1 coronavirus receptor ACE2 and the cellular protease TMPRSS2 for entry into target cells. bioRxiv preprint. 2020;2020:2020.01.31.929042. [Preprint].
5. Hamming I, Timens W, Bulthuis ML, Lely AT, Navis G, van Goor H. Tissue distribution of ACE2 protein, the functional receptor for SARS coronavirus. A first step in understanding SARS pathogenesis. J Pathol. 2004;203(2):631-7.
6. Fan C, Li K, Ding Y, Lu W, Wang J. ACE2 Expression in Kidney and Testis May Cause Kidney and Testis Damage After 2019-nCoV Infection. medRxiv preprint. 2020;2020:2020.02.12.20022418. [Preprint].
7. Xu H, Zhong L, Deng J, Peng J, Dan H, Zeng X, Li T, Chen Q. High expression of ACE2 receptor of 2019-nCoV on the epithelial cells of oral mucosa. Int J Oral Sci. 2020;12(1):8.
8. Zhang H, Kang Z, Gong H, Xu D, Wang J, Li Z, Cui X, Xiao J, Meng T, Zhou W, Liu J, Xu H. The digestive system is a potential route of 2019-nCov infection: a bioinformatics analysis based on single-cell transcriptomes. bioRxiv preprint. 2020;2020:2020.01.30.927806. [Preprint].
9. Zheng Q-L, Duan T, Jin L-P. Single-cell RNA expression profiling of ACE2 and AXL in the human maternal-fetal interface. Rep Dev Med. 2020 Feb 18. [Epub ahead of print].

10. Imai Y, Kuba K, Rao S, Huan Y, Guo F, Guan B, Yang P, Sarao R, Wada T, Leong-Poi H, Crackower MA, Fukamizu A, Hui CC, Hein L, Uhlig S, Slutsky AS, Jiang C, Penninger JM. Angiotensin-converting enzyme 2 protects from severe acute lung failure. Nature. 2005;436(7047):112-6.
11. Kuba K, Imai Y, Rao S, Jiang C, Penninger JM. Lessons from SARS: control of acute lung failure by the SARS receptor ACE2. J Mol Med (Berl). 2006;84(10):814-20.
12. Xu X, Han M, Li T, Sun W, Wang D, Fu B, Zhou Y, Zheng X, Yang Y, Li X, Zhang X, Pan A, Wei H. Effective Treatment of Severe COVID-19 Patients with Tocilizumab. chinaXiv. 2020;2020:202003.00026v1. [Preprint].
13. Cao Y, Li L, Feng Z, Wan S, Huang P, Sun X, Wen F, Huang X, Ning G, Wang W. Comparative genetic analysis of the novel coronavirus (2019-nCoV/SARS-CoV-2) receptor ACE2 in different populations. Cell Discov. 2020;6:11.
14. Chen J, Jiang Q, Xia X, Liu K, Yu Z, Tao W, Gong W, Han JJ. Individual Variation of the SARS-CoV2 Receptor ACE2 Gene Expression and Regulation. Preprints. 2020;2020:2020030191. [Preprint].
15. Fang L, Karakiulakis G, Roth M. Are patients with hypertension and diabetes mellitus at increased risk for COVID-19 infection? Lancet Respir Med. 2020 Mar 11. [Epub ahead of print].
16. Schouten LR, van Kaam AH, Kohse F, Veltkamp F, Bos LD, de Beer FM, van Hooijdonk RT, Horn J, Straat M, Witteveen E, Glas GJ, Wieske L, van Vught LA, Wiewel MA, Ingelse SA, Cortjens B, van Woensel JB, Bos AP, Walther T, Schultz MJ, Wösten-van Asperen RM; MARS consortium. Age-dependent differences in pulmonary host responses in ARDS: a prospective observational cohort study. Ann Intensive Care. 2019;9(1):55.
17. Chen H, Guo J, Wang C, Luo F, Yu X, Zhang W, Li J, Zhao D, Xu D, Gong Q, Liao J, Yang H, Hou W, Zhang Y. Clinical characteristics and intrauterine vertical transmission potential of COVID-19 infection in nine pregnant women: a retrospective review of medical records. Lancet. 2020;395(10226): 809-15.
18. Chen S, Huang B, Luo DJ, Li X, Yang F, Zhao Y, Nie X, Huang BX. [Pregnant women with new coronavirus infection: a clinical characteristics and placental pathological analysis of three cases]. [Article in Chinese]. Zhonghua Bing Li Xue Za Zhi. 2020 Mar 1. [Epub ahead of print].
19. Yang H, Wang C, Poon LC. Novel coronavirus infection and pregnancy. Ultrasound Obstet Gynecol. 2020 Mar 5. [Epub ahead of print].
20. Wang L, Shi Y, Xiao T, Fu J, Feng X, Mu D, Feng Q, Hei M, Hu X, Li Z, Lu G, Tang Z, Wang Y, Wang C, Xia S, Xu J, Yang Y, Yang J, Zeng M, Zheng J, Zhou W, Zhou X, Zhou X, Du L, Lee SK, Zhou W; Working Committee on Perinatal and Neonatal Management for the Prevention and Control of the 2019 Novel Coronavirus Infection. Chinese expert consensus on the perinatal and neonatal management for the prevention and control of the 2019 novel coronavirus infection (First edition). Ann Transl Med. 2020;8(3):47.
21. Favre G, Pomar L, Qi X, Nielsen-Saines K, Musso D, Baud D. Guidelines for pregnant women with suspected SARS-CoV-2 infection. Lancet Infect Dis. 2020 Mar 3. [Epub ahead of print].
22. Wang S, Guo L, Chen L, Liu W, Cao Y, Zhang J, Feng L. A case report of neonatal COVID-19 infection in China. Clin Infect Dis. 2020 Mar 12. [Epub ahead of print].
23. Cai JH, Wang XS, Ge YL, Xia AM, Chang HL, Tian H, Zhu YX, Wang QR, Zeng JS. [First case of 2019 novel coronavirus infection in children in Shanghai]. [Article in Chinese]. Zhonghua Er Ke Za Zhi. 2020;58(2):86-7.
24. Zeng LK, Tao XW, Yuan WH, Wang J, Liu X, Liu ZS. [First case of neonate infected with novel coronavirus pneumonia in China]. [Article in Chinese]. Zhonghua Er Ke Za Zhi. 2020 Feb 17. [Epub ahead of print].
25. Deng H, Zhang Y, Wang Y, Li F. [Two cases of 2019 novel coronavirus infection in children]. [Article in Chinese]. Chin Pediatr Emerg Med. 2020;27(22);81-3.
26. Lu Q, Shi Y. Coronavirus disease (COVID-19) and neonate: What neonatologist need to know. J Med Virol. 2020 Mar 01. [Epub ahead of print].
27. Wilder-Smith A, Chiew CJ, Lee VJ. Can we contain the COVID-19 outbreak with the same measures as for SARS? Lancet Infect Dis. 2020 Mar 5. [Epub ahead of print].
28. Li N, Han L, Peng M, Lv Y, Ouyang Y, Liu K, Yue L, Li Q, Sun G, Chen L, Yang L. Maternal and neonatal outcomes of pregnant women with COVID-19 pneumonia: a case-control study. medRxiv preprint. 2020;2020:2020.03.10.20033605. [Preprint].
29. Chen Y, Peng H, Wang L, Zhao Y, Zeng L, Gao H, Liu Y. Infants Born to Mothers With a New Coronavirus (COVID-19). Front Pediatr. 2020;8:104.
30. Zhu H, Wang L, Fang C, Peng S, Zhang L, Chang G, Xia S, Zhou W. Clinical analysis of 10 neonates born to mothers with 2019-nCoV pneumonia. Transl Pediatr. 2020;9(1):51-60.
31. Chen ZM, Fu JF, Shu Q, Chen YH, Hua CZ, Li FB, Lin R, Tang LF, Wang TL, Wang W, Wang YS, Xu WZ, Yang ZH, Ye S, Yuan TM, Zhang CM, Zhang YY. Diagnosis and treatment recommendations for pediatric respiratory infection caused by the 2019 novel coronavirus. World J Pediatr. 2020 Feb 5. [Epub ahead of print].
32. Shen K, Yang Y, Wang T, Zhao D, Jiang Y, Jin R, Zheng Y, Xu B, Xie Z, Lin L, Shang Y, Lu X, Shu S, Bai Y, Deng J, Lu M, Ye L, Wang X, Wang Y, Gao L; China National Clinical Research Center for Respiratory Diseases; National Center for Children's Health, Beijing, China; Group of Respirology, Chinese Pediatric Society, Chinese Medical Association; Chinese Medical Doctor Association Committee on Respirology Pediatrics; China Medicine Education Association Committee on Pediatrics; Chinese Research Hospital Association Committee on Pediatrics; Chinese Non-government Medical Institutions Association Committee on Pediatrics; China Association of Traditional Chinese Medicine, Committee on Children's Health and Medicine Research; China News of Drug Information Association, Committee on Children's Safety Medication; Global Pediatric Pulmonology Alliance. Diagnosis, treatment,

and prevention of 2019 novel coronavirus infection in children: experts' consensus statement. World J Pediatr. 2020 Feb 7. [Epub ahead of print].

33. Dong Y, Mo X, Hu Y, Qi X, Jiang F, Jiang Z, Tong S. Epidemiological Characteristics of 2143 Pediatric Patients With 2019 Coronavirus Disease in China. Pediatrics. 2020;2020:e20200702. [Preprint].
34. Brodin P. Why is COVID-19 so mild in children? Acta Pediatr. 2020 Mar 25. [Epub ahead of print].
35. Cai J, Xu J, Lin D, Yang Z, Xu L, Qu Z, Zhang Y, Zhang H, Jia R, Liu P, Wang X, Ge Y, Xia A, Tian H, Chang H, Wang C, Li J, Wang J, Zeng M. A Case Series of children with 2019 novel coronavirus infection: clinical and epidemiological features. Clin Infect Dis. 2020 Feb 28. [Epub ahead of print].
36. Kam KQ, Yung CF, Cui L, Lin Tzer Pin R, Mak TM, Maiwald M, Li J, Chong CY, Nadua K, Tan NWH, Thoon KC. A well infant with coronavirus disease 2019 (COVID19) with high viral load. Clin Infect Dis. 2020 Feb 28. [Epub ahead of print].
37. Wei M, Yuan J, Liu Y, Fu T, Yu X, Zhang ZJ. Novel Coronavirus Infection in Hospitalized Infants Under 1 Year of Age in China. JAMA. 2020 Feb 14. [Epub ahead of print].
38. Liu W, Zhang Q, Chen J, Xiang R, Song H, Shu S, Chen L, Liang L, Zhou J, You L, Wu P, Zhang B, Lu Y, Xia L, Huang L, Yang Y, Liu F, Semple MG, Cowling BJ, Lan K, Sun Z, Yu H, Liu Y. Detection of Covid-19 in Children in Early January 2020 in Wuhan, China. N Engl J Med. 2020 Mar 12. [Epub ahead of print].
39. Xu Y, Li X, Zhu B, Liang H, Fang C, Gong Y, Guo Q, Sun X, Zhao D, Shen J, Zhang H, Liu H, Xia H, Tang J, Zhang K, Gong S. Characteristics of pediatric SARS-CoV-2 infection and potential evidence for persistent fecal viral shedding. Nat Med. 2020;2020:s41591-020-0817-4.
40. Xia W, Shao J, Guo Y, Peng X, Li Z, Hu D. Clinical and CT features in pediatric patients with COVID-19 infection: Different points from adults. Pediatr Pulmonol. 2020 Mar 5. [Epub ahead of print].
41. Gao ZC. [Efficient management of novel coronavirus pneumonia by efficient prevention and control in scientific manner]. [Article in Chinese]. Zhonghua Jie He He Hu Xi Za Zhi. 2020 Feb 5. [Epub ahead of print].
42. The Italian Society of Tropical Medicine and Global Health (SIMIT). Vademecum per la cura delle persone con malattia da COVID-19. Versione 2.0, 13 marzo 2020. Available at: http://www.simit.org/medias/1568-covid19-vademecum-20-13-marzo-2020.pdf, date of publication: 13 March 2020, last access: 26 March 2020.
43. Chen L, Xiong J, Bao L, Shi Y. Convalescent plasma as a potential therapy for COVID-19. Lancet Infect Dis. 2020 Feb 27. [Epub ahead of print].
44. Lu X, Zhang L, Du H, Zhang J, Li YY, Qu J, Zhang W, Wang Y, Bao S, Li Y, Wu C, Liu H, Liu D, Shao J, Peng X, Yang Y, Liu Z, Xiang Y, Zhang F, Silva RM, Pinkerton KE, Shen K, Xiao H, Xu S, Wong GWK; the Chinese Pediatric Novel Coronavirus Study Team. SARS-CoV-2 Infection in Children. N Engl J Med. 2020;2020:NEJMc2005073.
45. Dong L, Tian J, He S, Zhu C, Wang J, Liu C, Yang J. Possible Vertical Transmission of SARS-CoV-2 From an Infected Mother to Her Newborn. JAMA. 2020 Mar 26. [Epub ahead of print].
46. Kimberlin DW, Stagno S. Can SARS-CoV-2 Infection Be Acquired In Utero? More Definitive Evidence Is Needed. JAMA. 2020 Mar 26. [Epub ahead of print].
47. Davanzo R, Mosca F, Moro G, Sandri F, Agosti M; the Italian Society of Neonatology (SIN). Allattamento e infezione da SARS-CoV-2 (Coronavirus Disease 2019 – COVID-19). Indicazioni ad interim della Società Italiana di Neonatologia (SIN). Versione 2. Available at: https://www.sin-neonatologia.it/wp-content/uploads/2020/03/LM.SIN_.V2.COVID_.19-2.pdf, date of publication: 22 March 2020, last access: March 27 2020.
48. Binns C, Lee M, Low WY. The Long-Term Public Health Benefits of Breastfeeding. Asia Pac J Public Health. 2016;28(1):7-14.
49. Le Monde; AFP. Coronavirus en France: aggravation rapide de l'épidémie avec 365 morts en 24 heures. Depuis le début de l'épidémie, le coronavirus a tué près de 1700 personnes en France, dont une jeune fille de 16 ans, morte en Ile-de-France. Available at: https://www.lemonde.fr/planete/article/2020/03/26/epidemie-due-au-coronavirus-en-france-l-armee-en-renfort-face-a-l-arrivee-de-jours-difficiles_6034456_3244.html, date of publication: 26 March 2020, last access: 28 March 2020.